

Safety, Efficacy, and Indications of β -Adrenergic Receptor Blockade to Reduce Heart Rate prior to Coronary CT Angiography¹

Amir A. Mahabadi, MD
 Stephan Achenbach, MD
 Christof Burgstahler, MD
 Thorsten Dill, MD
 Roman Fischbach, MD
 Andreas Knez, MD
 Werner Moshage, MD
 Barbara M. Richartz, MD
 Dieter Ropers, MD
 Stephen Schröder, MD
 Sigmund Silber, MD
 Stefan Möhlenkamp, MD
 For the working group "Cardiac CT" of the
 German Cardiac Society

For selected indications, coronary computed tomographic (CT) angiography is an established clinical technology for evaluation in patients suspected of having or known to have coronary artery disease. In coronary CT angiography, image quality is highly dependent on heart rate, with heart rate reduction to less than 60 beats per minute being important for both image quality and radiation dose reduction, especially when single-source CT scanners are used. β -Blockers are the first-line option for short-term reduction of heart rate prior to coronary CT angiography. In recent years, multiple β -blocker administration protocols with oral and/or intravenous application have been proposed. This review article provides an overview of the indications, efficacy, and safety of β -blockade protocols prior to coronary CT angiography with respect to different scanner techniques. Moreover, implications for radiation exposure and left ventricular function analysis are discussed.

© RSNA, 2010

¹From the Department of Cardiology, West German Heart Center, University Clinic Duisburg-Essen, Hufelandstrasse 55, 45122 Essen, Germany (A.A.M., S.M.); Department of Cardiology, University of Erlangen, Erlangen, Germany (S.A., D.R.); Department of Internal Medicine—Sports Medicine, University of Tübingen, Tübingen, Germany (C.B.); Sana Kliniken Düsseldorf, Düsseldorf, Germany (T.D.); Department of Radiology, Neuroradiology and Nuclear Medicine, Asklepios Klinik Altona, Hamburg, Germany (R.F.); Department of Cardiology, Klinikum Weilheim, Weilheim, Germany (A.K.); Department of Internal Medicine—Cardiology, Klinikum Traunstein, Traunstein, Germany (W.M.); Heart Diagnostic Center, Munich, Germany (B.R., S. Silber); and Department of Cardiology, Klinik am Eichert, Göppingen, Germany (S. Schröder). Received January 25, 2010; revision requested March 2; revision received March 23; accepted April 20; final version accepted April 27; final review by S.M. June 30. A.A.M. supported by a grant from the German National Academic Foundation. S.A. supported by grant BMBF 01 EV 0708, from Bundesministerium für Bildung und Forschung, Bonn, Germany. **Address correspondence to S.M.** (e-mail: stefan.moehlenkamp@uk-essen.de).

Coronary computed tomographic (CT) angiography is an established clinical technology for the evaluation of coronary artery disease, with high sensitivity and high negative predictive value in selected patients. Furthermore, it has potential for the detection of coronary plaque burden (1–3). Over the past decade, advances in scanner and postprocessing technology have led to substantial improvements in temporal and spatial resolution and hence image quality. Yet image quality remains highly dependent on both the regularity of the cardiac rhythm and the heart rate, especially when single-source CT scanners are used, which to date represent the vast majority of scanners in clinical practice. Current publications recommend a heart rate of ideally less

than 60 beats per minute both for optimal image quality and for reduction of radiation exposure (4). However, most patients seen in clinical practice have heart rates often much above 75 beats per minute at presentation (5–7). Therefore, in the absence of contraindications, β -blockers should be routinely administered prior to coronary CT angiography to achieve sufficient reduction of heart rate prior to data acquisition. However, a recent survey showed that about 50% of 141 centers in the United States using 64-detector CT for coronary CT angiography allow heart rates faster than 70 beats per minute for coronary CT angiography, while target heart rate was defined as less than 60 beats per minute in 64% and less than 65 beats per minute in 89% of participating centers (8). Furthermore, all centers where scanning was exclusively performed by cardiologists used a target heart rate of less than 65 beats per minute, whereas 18% of radiologists set a higher target (8). A similar survey among 45 centers performing cardiac CT in Germany reported that only 86% of centers routinely used β -blockers for patient preparation, while the median heart rate threshold was 70 beats per minute (9). These results indicate the need for more effective heart rate reduction in clinical practice.

In this article, we provide an overview of indications, safety, and efficacy of β -blockade prior to coronary CT angiography, for a number of different application protocols. Furthermore, we discuss implications for radiation exposure and ventricular function analysis with respect to current developments in scanner technique, as well as alternatives to β -blockers.

Pharmacologic Properties of β -Blockers

To reduce heart rate during coronary CT angiography, cardioselective (β_1) β -blockers are the predominantly used agents. β -Adrenergic antagonists reduce the heart rate by decreasing the frequency of the sinus node, by decreasing the spontaneous rate of depolarization of ectopic pacemakers, by slowing conduction

in the atria and in the atrioventricular node, and by increasing the functional refractory period of the atrioventricular node. Pharmacologic properties of short-term β -blockers, such as decreasing cardiac output and peripheral resistance, differ substantially from long-acting β -blockers, when total peripheral resistance returns to initial values (Table 1; effects mediated by β -adrenoreceptors) (10). β -Blockers as a daily medication—for example, for heart failure—have only mild influence on resting heart rates and mainly reduce maximum heart rates achieved during exercise (11). However, when administered as short-term medication in high doses, they also allow reduction of heart rate at rest, as desired for cardiac CT. As a trade-off, β -blockers can then cause substantial side effects because of their β_1 selectivity, intrinsic sympathomimetic activity, and membrane-stabilizing properties. These include hypotension, bradycardia, prolonged atrioventricular conduction times, and widened QRS complexes. Of importance, especially in high doses, cardioselective β -blockers also bind on β_2 receptors, which can cause a number of noncardiac side effects. Blockade of β_2 receptors with compensatory sympathetic reflexes that activate vascular α -adrenergic receptor can cause peripheral vasoconstriction, which reduces blood flow to most organs other than the brain, including a decrease in renal blood flow and glomerular filtration rate (12). Fortunately, the decrease in peripheral blood flow is seen clinically only in the acral skin, usually without any pathologic relevance.

Metoprolol (β_1 selective) is the most commonly used β -blocker for heart rate reduction. Its oral bioavailability is relatively low (40%) with high interindividual

Essentials

- β -Adrenergic receptor blockade is the first-line treatment for reducing heart rate in patients undergoing coronary CT angiography; in the absence of contraindications, short-term high-dose β -blocker administration is safe and leads to effective heart rate reduction in the majority of patients.
- Oral and intravenous routes of β -blocker administration are both first-line options; in case of oral administration, non-sustained release forms of β -blockers should be used.
- By virtue of their heart rate-lowering effect, β -blockers result in an improved image quality and diagnostic accuracy of coronary CT angiography examinations.
- Although some techniques and protocols (eg, dual-source CT, multisegment reconstruction) may not require fixed target heart rates for optimal image quality, heart rate reduction allows effective use of prospective triggering, tube current modulation, or single volume data acquisition, which significantly reduces radiation exposure.

Published online

10.1148/radiol.10100140

Radiology 2010; 257:614–623

S.A. received research grants from Siemens Healthcare and Bayer Schering Pharma and is a consultant for Servier, Bracco, and GE Healthcare. S.M. received research grants from Merck and GE Healthcare, and speaker honoraria from Toshiba, Siemens Healthcare, GE Healthcare, Servier, Daiichi Sankyo, and Pfizer.

differences due to high first-pass metabolism with wide variation (13). Therefore, intravenous administration (bioavailability 95%) is not only beneficial because it results in faster reduction of heart rate, but it also allows better dose titration. Intravenously, 2.5 or 5 mg metoprolol should be administered over 1–2 minutes, which can be repeated at approximately 2–5-minute intervals. Despite its half-life of 3–4 hours, it is usually intravenously administered immediately prior to the CT scan. Other used β -blockers are atenolol (oral bioavailability 40%–50%, half-life of 6–7 hours) and, less frequently, esmolol with a half-life of only 9 minutes, which can be applied as bolus injection immediately prior to the CT scan or as continuous infusion with careful titration of dose, until effective heart rate reduction is achieved (Table 2).

Protocols for β -Blocker Administration prior to Coronary CT Angiography

Several studies have addressed the effect of oral, intravenous, or combinations of

oral and intravenous β -blocker administration in clinical practice (Table 3). Overall, intravenous administration is associated with higher heart rate reduction. About 65% of subjects with heart rates greater than 65 beats per minute were reduced to less than 65 beats per minute by intravenous administration of esmolol at 1–3 mg per kilogram of body weight (14). Only 1% had remaining heart rates greater than 80 beats per minute despite β -blocker administration. In contrast, only 35% of 150 subjects reached a target heart rate of less than 65 beats per minute by means of intravenous administration of 5–20 mg (mean, 12 mg) of metoprolol 5 minutes prior to the scan (5). A retrospective analysis of 560 consecutive patients comparing oral metoprolol (100–200 mg administered 1 hour prior to the scan) and intravenous atenolol (5–10 mg administered 5–10 minutes prior to the scan) showed that intravenous β -blockade led to significantly lower preimaging heart rates than did oral application (55 beats per minute \pm 5 [standard deviation] vs 60 \pm 7), with

81.1% of the subjects overall achieving the target heart rate of 65 beats per minute. Heart rate reduction was slightly more pronounced after intravenous compared with oral β -blockade (–16 beats per minute \pm 8 vs –14 beats per minute \pm 9). Moreover, the desired therapeutic effect with intravenous administration occurred significantly faster than with oral administration, allowing patient preparation in 8 minutes \pm 9 versus 62 minutes \pm 22 (6). On the other hand, preparation for oral β -blockade occurs outside the CT scanner and typically does not decrease patient throughput as compared with intravenous β -blocker administration. Oral metoprolol administered 1 hour before scanning has been reported to be effective, especially in patients without prior medication, and therefore can help reduce the need of intravenous β -blocker administration. If the target heart rate is not achieved, additional intravenous β -blocker administration should be performed prior to the scan (15). Some use intravenous metoprolol (14) and others use esmolol (16) to a similar effect. The maximum dose of intravenous metoprolol for coronary CT angiography reported in the literature generally ranges from 10 to 30 mg (5,17–20).

β -Blockers may also diminish the increase in heart rate caused by nitroglycerine, which is routinely given prior to coronary CT angiography to improve the diagnostic accuracy of the examination (4,21).

Because of the simplicity of its use, its reported efficacy in many patients, its well-known safety profile in routine clinical practice, and the extensive experience with oral application in many institutions, oral β -blockade is a first-line option to reduce elevated heart rates, which should be supplemented by intravenous β -blockers as needed (Figure). Of importance, non-sustained-release forms of oral β -blockers should be used to obtain the desired short-term effect. Single or repeat intravenous injections of β -blockers have the advantage that the required dose can be titrated until the target heart rate is reached, and they are as safe as oral agents when administered appropriately. Use of

Table 1

Selected Effects Mediated by β -Adrenergic Receptors

Tissue	β Receptor type	Effect
Heart		
SA node	β_1 and β_2	Increase in heart rate
AV node	β_1 and β_2	Increase in conduction velocity
Atria	β_1 and β_2	Increase in contractility
Ventricles	β_1 and β_2	Increase in contractility
Arteries	β_2	Vasodilation
Veins	β_2	Vasodilation
Bronchi	β_2	Brochodilation
Gastrointestinal	β_2	Relaxation
Nerve terminals	β_2	Increase in noradrenaline release

Note.—Selected effects as reported in reference 11. AV = atrioventricular, SA = sinoatrial.

Table 2

Pharmacologic Characteristics of β -Blockers for Short-term Heart Rate Reduction Prior to Cardiac CT Angiography

Drug	β , Selectivity	Intrinsic Activity	Oral Bioavailability (%)	Half-life in Plasma
Metoprolol	Yes	No	40	3–4 h
Atenolol	Yes	No	50	5–8 h
Esmolol	Yes	No		9 min

Table 3

Effectiveness of β -Blocker Protocols

Study	No. of Patients Undergoing Heart Rate Reduction	β -Blocker Protocol	Mean Heart Rate Reduction (beats/min)	Patients with Heart Rate Reduction (<65 beats/min) after Treatment (%)
Shapiro et al (5)	52	5–20 mg metoprolol, intravenously	6 \pm 7	35
Pannu et al (15)	122	25–100 mg oral metoprolol, and additional intravenous metoprolol if needed	19.3	NA
Maffei et al (6)	285	100–200 mg metoprolol, orally	14 \pm 8	81.1 (overall)
	69	5–10 mg atenolol, intravenously	16 \pm 9	
Roberts et al (18)	71	100 mg metoprolol orally 1 h prior, and additional 5–15 mg intravenously if needed	17 \pm 9.5	83
Degertekin et al (14)	391	1–2 mg/kg esmolol intravenously, and additional 50 mg oral atenolol if baseline heart rate > 90 beats/min	17	65

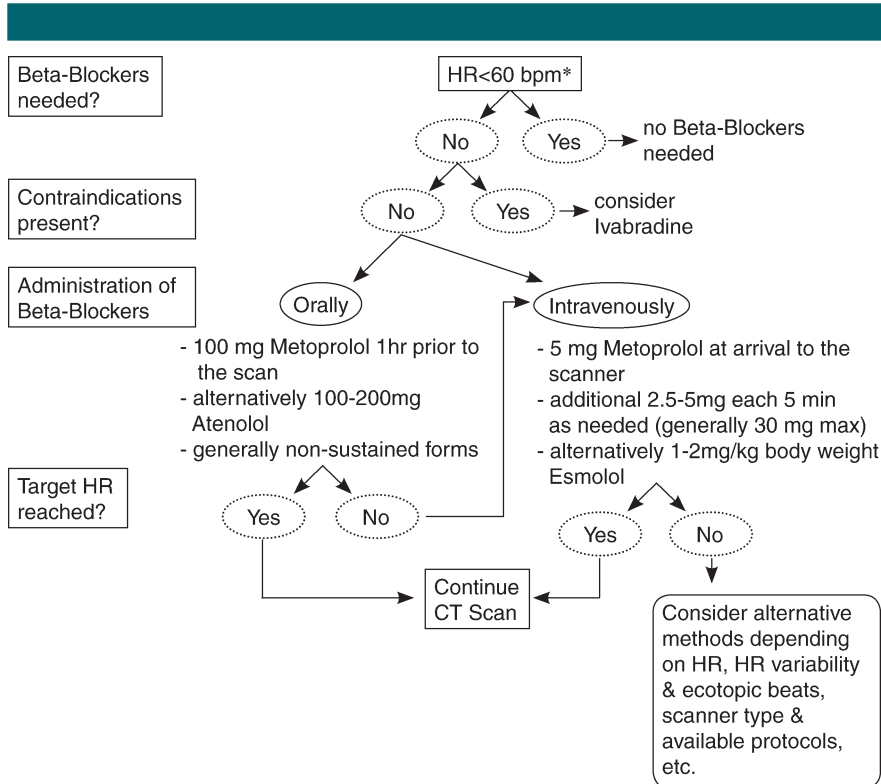
Note.—NA = not applicable.

intravenously administered β -blockers is therefore also considered an alternative first-line option.

In the studies and clinical reports in the literature, a considerable number of patients (5%–11%) did not qualify for treatment with β -blockers owing to contraindications (5,6,18). In these subjects, calcium-channel blockers such as verapamil or diltiazem are mentioned in the literature as potential alternatives (5,6). However, from clinical experience, the effectiveness of calcium-channel blockers for short-term heart rate reduction is considerably less than that of β -blockers. Calcium-channel blockers have not been systematically studied for this purpose and they are not recommended as a useful means of sufficient heart rate reduction in cardiac CT. However, ivabradine may be an effective alternative (see below).

Effects of Heart Rate on Image Quality

High heart rates during CT scanning limit the image quality. The higher the heart rate, the higher the likelihood of motion artifacts that can considerably diminish the diagnostic accuracy of the scan (22–26). In a large study including 378 participants undergoing coronary CT angiography and a total of 6253 coronary segments evaluated, the odds for nonevaluable segments were 1.35 (95% confidence interval: 1.11, 1.67; $P = .003$) per each 10 beats per minute



Flowchart for the use of β -blockers as short-term medication for heart rate reduction prior to cardiac CT. * = In agreement with Society of Cardiovascular Computed Tomography guidelines (4). bpm = beats per minute, HR = heart rate.

(27). Generally, motion artifacts are especially prominent in the mid right coronary artery, where the rapid translational movement of the vessel may be as much as five to six times its diameter during the twisting and torsion of

the heart during the cardiac cycle (28). Therefore, the need for β -blockade prior to multidetector CT scanning to lower the heart rate in most patients referred for coronary CT angiography has been acknowledged in recent statements by

the American Heart Association, Society of Cardiovascular Computed Tomography, and American College of Radiology (4,28,29).

If heart rate reduction is achieved, this usually translates into better image quality. With use of a 64-detector CT scanner, only 1% of subjects who reached a target heart rate of 60 beats per minute were reported to have relevant motion artifacts, while one of two patients had motion artifacts if the heart rate was greater than 70 beats per minute (18). An increase in odds of misalignment (“stair step”) artifacts of 11.6% per 1 beat per minute increase of heart rate in logistic regression was described. Moreover, in a different study using 64-detector CT, the imaging studies were diagnostic in all subjects who reached target heart rate (<65 beats per minute), while 7% of studies were nonevaluable, if subjects had heart rates of 65 beats per minute or greater (5). In addition to resting heart rate, heart rate variability also has implications on image quality (30). With β -blockade, the heart rate displayed substantially lower variability (2.45 beats per minute \pm 1.53 vs 4.29 beats per minute \pm 2.25), which also resulted in better image quality, even if heart rates were less than 65 beats per minute (30).

With improvements in temporal resolution on new scanner technologies such as dual-source CT or 320-detector CT, there is growing evidence that a restrictive heart rate reduction may not be needed, with reports of sufficient image quality even at heart rates of up to 110 beats per minute (31–36). However, even for scanners with an effective temporal resolution under 100 msec, slightly lower per-segment evaluability for high heart rates have been described, yet without decrease in overall diagnostic accuracy (37). Further studies showed that also in dual-source CT, accuracy and image quality are higher at lower heart rates (38). Overall, to date there is an ongoing debate whether heart rate reduction is needed for retrospectively gated dual-source CT imaging. Further research is needed to better characterize the association between various target heart rates and

heart rate variability with image quality in new scanner generations with improved temporal resolution.

Atrial Fibrillation and Frequent Ectopic Beats

In subjects with frequent ventricular or supraventricular ectopic heart beats, β -blockers are potentially useful due to their membrane-stabilizing properties and therefore their ability to decrease the spontaneous rate of depolarization of ectopic pacemakers. In subjects with atrial fibrillation, there are still conflicting data on the image quality even with new scanner generations with low temporal resolution. While initial experience suggested successful imaging in patients with atrial fibrillation (39), others found a high number of segments with motion artifacts (27% with misalignment artifacts, only 12% free of artifacts) in patients with heart rate irregularities including atrial fibrillation, which resulted in limited overall accuracy despite the increased temporal resolution of dual-source CT (40). Likewise, a high rate of evaluable segments but significantly lower image quality has been reported for subjects with atrial fibrillation with use of 320-detector CT (36). Overall, more research is needed to further evaluate the diagnostic accuracy of coronary CT angiography in subjects with arrhythmias such as atrial fibrillation and to determine if reduction of heart rate and decrease of the rate of spontaneous depolarization of ectopic pacemakers by short-term β -blocker treatment may help to improve image quality in these patients.

Implications of Heart Rate Reduction on Radiation Exposure

In clinical practice, an increase in heart rate by 10 beats per minute was found to lead to a 5% increase in radiation exposure; this was reported in an international observational study with 50 sites that included a wide range of CT hardware (41). Several algorithms have been developed to allow for direct or indirect reduction in radiation exposure, but all of these algorithms are more effective at lower heart rates.

Electrocardiographically Correlated X-ray Tube Current Modulation

When retrospective gating is applied for coronary CT angiography, x-ray data are acquired throughout the entire cardiac cycle, which allows reconstruction at any desired phase of the R-R interval. For coronary artery evaluation, which requires best image quality, phases during end diastole are usually reconstructed, while other phases are less frequently used for coronary CT angiography. Therefore, tube current can be reduced (typically by 80%) during remaining parts of the cardiac cycle. During this time, contrast-to-noise ratio is decreased but usually still allows sufficient image quality for function analysis at lower radiation exposure (see below). However, effectiveness of tube current modulation decreases with increasing heart rates, since the relative length of the time during which tube current is reduced is shorter than with lower heart rates (42–45).

Prospective Electrocardiographic Triggering (“Step-and-Shoot” Mode)

With prospective electrocardiographic triggering, the x-ray tube is turned on only during a certain previously defined phase of the R-R interval, and images can be reconstructed only at this one particular phase. Therefore, a low and regular heart rate is of particular importance to ensure diagnostic image quality, as variation in heart rates or ventricular ectopic beats would lead to severe stair-step artifacts and reconstruction at other phases is not possible if motion artifacts are present. The higher temporal resolution of dual-source CT scanners or scanners with high rotation speed theoretically allows for high-quality scans at higher heart rates. Yet, if prospective triggering is used, the likelihood of motion artifacts can also be reduced for dual-source CT scanners by using β -blockers, because the resultant reduction in heart rate and heart rate variability increases the phase window of the R-R interval during which artifact-free imaging is possible (46). Therefore, β -blockers can help to achieve diagnostic image quality in radiation-saving prospectively triggered

coronary CT angiography irrespective of the scanner type used (47).

Multisegment Reconstruction

The idea is to decrease the duration of the window used for image reconstruction by combining data from consecutive heart beats. With single-source CT scanners, data sets can retrospectively be reconstructed from several heart beats by using multisegment reconstruction. Therefore, retrospective electrocardiographically gated spiral modes at a low pitch are needed for image acquisition. In contrast to retrospective multisegment reconstruction, using 320-section CT, which allows for full volume scanning during a single heart beat at heart rates of less than 65 beats per minute, images can be prospectively acquired at heart rates greater than 65 beats per minute from up to four consecutive heartbeats and therefore reconstructed from up to four different segments of one tube rotation (48). It has been suggested that this would reduce the need for routine β -blockade. However, multisegment reconstruction is associated with higher radiation exposure due to the required low pitch or multiple scans of the same volumes. It therefore may be preferable to lower the heart rate and avoid the necessity of multisegment reconstruction to limit radiation exposure (16).

High-Pitch Spiral Acquisition

There are recent reports on high-pitch spiral acquisition ("flash spiral") with potential for further reduction of radiation exposure, resulting in a total effective dose of less than 1 mSv (17,49–51). However, these protocols also require a stable and low heart rate (according to currently published data, <60 beats per minute) to achieve reliable triggering and to complete the entire data acquisition during the diastole of one cardiac cycle.

Influence of β -Blocker Treatment on Ventricular Function Analysis

When coronary CT angiograms are acquired with retrospective gating, images throughout the cardiac cycle are available to the physician. These allow

three-dimensional evaluation of systolic and diastolic left ventricular volume, left ventricular ejection fraction, left ventricular mass, and left atrial volume without additional radiation exposure or contrast agent administration (20,52–55). However, in the context of high-dose β -blocker administration, findings from functional analysis could be altered, given its negative chronotropic, dromotropic, and inotropic effect. Left ventricular end-systolic and end-diastolic volumes, ejection fraction, mass, stroke volume, and cardiac output from dual-source CT examinations were recently compared with and without β -blockers and cardiac magnetic resonance (MR) examinations. While left ventricular volumes and function analysis was not different in subjects without β -blockade during dual-source CT compared with MR imaging, the group receiving β -blockers (intravenous metoprolol, 5–30 mg) had significantly lower ejection fraction, stroke volume, and cardiac output with significantly increased end-systolic volume. Only end-diastolic volume and myocardial mass were not affected (20). Likewise, significantly lower stroke volume and ejection fraction at 16-section multidetector CT were found in comparison with those at MR imaging, when all subjects received β -blockers prior to CT and consecutively had lower heart rates (56). This finding is in good agreement with prior animal and patient studies that demonstrated the significant reduction of ejection fraction, stroke volume, and cardiac output with β -blocker treatment (57–59). Moreover, atenolol alters the relaxation process of the myocardium (60). Taken together, these findings indicate that β -blocker application prior to coronary CT angiography may theoretically diminish the diagnostic value of left ventricular function analysis. However, all currently available reports are limited by the low number of subjects. Further studies are needed to evaluate the role of short-term high-dose β -adrenergic antagonist administration on global and regional ventricular function. Additionally, research is needed to assess whether β -blockers also affect left atrial volumes (61). If functional

analysis is of special interest in addition to coronary CT angiography, ivabradine may be a useful alternative to β -blockers since it does not impair myocardial contractility (see below).

Safety

When β -adrenergic blockers are administered as short-term high-dose medication prior to coronary CT angiography, safety is of concern, and screening for potential side effects can be mandatory even in the postprocedural phase (62). For prevention of side effects, contraindications must be considered (Table 4). In addition, β -blockers may trigger or aggravate symptoms of some medical conditions such as aortic stenosis, carotid stenosis, or pulmonary embolism. The latter is of particular relevance for triple-rule-out protocols. β -Blockers may further impair hemodynamics in severe pulmonary embolism, while being among first-line options in aortic dissection and acute coronary syndrome. The use of β -blockers has been reported for triple-rule-out protocols but should be considered individually, especially in the acute setting (63,64). While indications for long-term β -blocker therapy in patients undergoing antidiabetic therapy need to be evaluated individually, there is no relevant contraindication for the short-term use of β -blockers in patients with diabetes. In summary, the use of β -blockers requires in-depth knowledge of contraindications, adverse effects, and interactions with other drugs, which have been well described in a recent review (Table 4) (65).

Overall, if contraindications are ruled out, side effects attributable to pharmacologic treatment are rare. For instance, no adverse event could be attributed to β -blockers in a retrospective analysis of 471 subjects that received oral or intravenous β -blockers prior to multidetector CT examinations (6). This is in accordance with other reports of oral metoprolol administration (15,18). In an evaluation of the safety of esmolol, a rapidly metabolizing β -blocker, four (1%) of 391 subjects had a final heart rate below 50 beats per minute as an overshooting effect of esmolol, which

Table 4

Frequent Contraindications, Adverse Events, and Drug Interactions for the Use of β -Blockers

Category	Description
Contraindication	(Allergic) asthma bronchiale or severe chronic obstructive pulmonary disease; Atrioventricular block type II Mobitz or type III; Severe bradycardia (heart rate <50 beats/min); Severe hypotension (systolic blood pressure <100 mm Hg); Acute congestive heart failure; Allergy to the β -blocker or its constituents
Adverse event	Bronchospasm Bradycardia Atrioventricular block Hypotension Raynaud phenomenon Allergic reaction
Drug interaction	Calcium-channel blockers such as verapamil and diltiazem: potential additive depressive effect on the sinus and atrioventricular node; Alcohol, phenytoin, rifampicin, and phenobarbital: induction of hepatic biotransformation of lipophilic β -blockers (eg, metoprolol); Aluminum salts, cholestyramine, and colestipol: potential decrease in absorption of β -blockers

resolved in minutes without any intervention in all subjects (14). Therefore, the authors concluded that prolonged side effects of esmolol are avoided due to its short half-life. Following oral administration of β -blockers, post-CT monitoring is usually not required; following intravenous administration, surveillance of heart rate and blood pressure should be available and its use considered individually. If the patient develops symptoms due to bradycardia, a rapid intravenous injection of 0.5–1 mg of atropine is usually effective and can be repeated up to a maximum dose of about 3 mg. If the patient is symptomatic from hypotension, 10–20 mL of intravenous fluids per kilogram of body weight should be administered as a bolus dose. Clinically, side effects due to β -blocker application need to be distinguished from allergic reaction to iodinated contrast media (66). The latter can present with mild symptoms such as skin rash, itching, nasal discharge, or nausea, but also can cause facial or laryngeal edema, bronchospasm, dyspnea, or heart rate irregularities that can lead to life-threatening conditions. Mild cases can be treated with oral or intravenous antihistamines, if necessary. In severe cases, securing the airway or

administering intravenous epinephrine may become necessary (66).

Frequently, combinations of different β -adrenergic blockers are used to achieve low heart rates (6). However, as there are only limited data on safety, the use of protocols combining different β -blockers should be considered individually.

Ivabradine

Ivabradine is a pure heart rate–lowering agent that acts by inhibiting I_p , an important ionic current involved in the pacemaker activity in cells of the sinoatrial node, with no effect on the duration or morphology of the action potential (67,68). Ivabradine reduces the slope of spontaneous diastolic depolarization in these cells and lowers heart rate at rest and during exercise (68). At therapeutic concentrations, ivabradine does not depress myocardial contractility or intracardiac conduction and has only minor effects on blood pressure (68). Ivabradine shows a “use dependence,” that is, a more pronounced effect at higher heart rates. It is available at 5.0 or 7.5 mg per os and is given twice daily. Plasma levels peak after 1–2 hours with a bioavailability of 40%. At heart rates of

more than 85 beats per minute, heart rate reduction is about 20 beats per minute, but reduction is only about five beats per minute at heart rates lower than 65 beats per minute (69,70). Accordingly, symptomatic bradycardia is very rare, and the drug can also safely be used in the presence of concomitant β -blocker use (68). Ivabradine therefore is a potential alternative or adjunct to β -blockade for heart rate reduction during cardiac CT scanning. Initial experience suggests that more than one dose may be required to sufficiently reduce heart rates. However, to date, little is known about safe and effective dosing intervals. Additionally, contraindications for the use of ivabradine also have to be considered, including acute myocardial infarction and unstable angina, heart failure (New York Heart Association functional classes II–IV), severe hypotension, sick sinus syndrome or sinoatrial block, atrioventricular block of third degree, and severe hepatic insufficiency or combination with strong cytochrome P450 3A4 inhibitors. Furthermore, ivabradine is currently not available for intravenous administration and, to date, information is lacking regarding which time intervals of application of ivabradine prior to the scan are necessary to most effectively reduce heart rate. Studies are ongoing to assess the effectiveness of ivabradine for short-term heart rate reduction prior to coronary CT angiography. Of note, ivabradine is approved in Europe, Australia, and other parts of the world; however, it is not available in the United States, Canada, or Japan.

Summary Statements

1. β -Adrenergic receptor blockade is the first-line treatment to reduce heart rate in subjects undergoing coronary CT angiography. In the absence of contraindications, short-term high-dose β -blocker administration is safe. It leads to effective heart rate reduction in the majority of patients.

2. Metoprolol and then atenolol are the most frequently used β -blockers. Oral and intravenous routes of administration are both first-line options. In case of oral

administration, non-sustained release forms of β -blockers should be used. Oral application is easier and less invasive than intravenous administration but may not always sufficiently reduce heart rates. If target heart rates are not achieved, additional single or repetitive individually determined intravenous doses of β -blockers should be considered.

3. By virtue of their heart rate-lowering effect, β -blockers result in an improved image quality and diagnostic accuracy at coronary CT angiography.

4. Some scanning techniques and protocols, including dual-source CT, multisegment reconstruction, and increased rotation speed, may not necessarily require fixed target heart rates for optimal image quality. Yet, heart rate reduction allows for prospective triggering, tube current modulation, or single volume data acquisition, which significantly reduces radiation exposure.

References

1. Miller JM, Rochitte CE, Dewey M, et al. Diagnostic performance of coronary angiography by 64-row CT. *N Engl J Med* 2008; 359(22):2324–2336.
2. Budoff MJ, Dowe D, Jollis JG, et al. Diagnostic performance of 64-multidetector row coronary computed tomographic angiography for evaluation of coronary artery stenosis in individuals without known coronary artery disease: results from the prospective multicenter ACCURACY (Assessment by Coronary Computed Tomographic Angiography of Individuals Undergoing Invasive Coronary Angiography) trial. *J Am Coll Cardiol* 2008;52(21):1724–1732.
3. Hoffmann U, Bamberg F, Chae CU, et al. Coronary computed tomography angiography for early triage of patients with acute chest pain: the ROMICAT (Rule Out Myocardial Infarction using Computer Assisted Tomography) trial. *J Am Coll Cardiol* 2009; 53(18):1642–1650.
4. Abbara S, Arbab-Zadeh A, Callister TQ, et al. SCCT guidelines for performance of coronary computed tomographic angiography: a report of the Society of Cardiovascular Computed Tomography Guidelines Committee. *J Cardiovasc Comput Tomogr* 2009;3(3):190–204.
5. Shapiro MD, Pena AJ, Nichols JH, et al. Efficacy of pre-scan beta-blockade and impact of heart rate on image quality in patients undergoing coronary multidetector computed tomography angiography. *Eur J Radiol* 2008; 66(1):37–41.
6. Maffei E, Palumbo AA, Martini C, et al. "In-house" pharmacological management for computed tomography coronary angiography: heart rate reduction, timing and safety of different drugs used during patient preparation. *Eur Radiol* 2009;19(12):2931–2940.
7. Achenbach S, Ropers U, Kuettner A, et al. Randomized comparison of 64-slice single- and dual-source computed tomography coronary angiography for the detection of coronary artery disease. *JACC Cardiovasc Imaging* 2008;1(2):177–186.
8. Johnson PT, Eng J, Pannu HK, Fishman EK. 64-MDCT angiography of the coronary arteries: nationwide survey of patient preparation practice. *AJR Am J Roentgenol* 2008; 190(3):743–747.
9. Maurer MH, Hamm B, Dewey M. Survey regarding the clinical practice of cardiac CT in Germany: indications, scanning technique and reporting. *Rofo* 2009;181(12):1135–1143.
10. Mimran A, Ducaïlar G. Systemic and regional haemodynamic profile of diuretics and alpha- and beta-blockers. A review comparing acute and chronic effects. *Drugs* 1988;35(suppl 6):60–69.
11. Hoffman BB. Catecholamines, sympathomimetic drugs, and adrenergic receptor antagonists. In: Hardman JG, Limbird LE, Goodman L, Gilman A, eds. *Goodman Gilman's the pharmacological basis of therapeutics*. New York, NY: McGraw-Hill, 2001.
12. Epstein M, Oster JR. Beta-blockers and the kidney. *Miner Electrolyte Metab* 1982; 8(5):237–254.
13. Benfield P, Clissold SP, Brogden RN. Metoprolol: an updated review of its pharmacodynamic and pharmacokinetic properties, and therapeutic efficacy, in hypertension, ischaemic heart disease and related cardiovascular disorders. *Drugs* 1986;31(5):376–429.
14. Degertekin M, Gemicci G, Kaya Z, et al. Safety and efficacy of patient preparation with intravenous esmolol before 64-slice computed tomography coronary angiography. *Coron Artery Dis* 2008;19(1):33–36.
15. Pannu HK, Sullivan C, Lai S, Fishman EK. Evaluation of the effectiveness of oral beta-blockade in patients for coronary computed tomographic angiography. *J Comput Assist Tomogr* 2008;32(2):247–251.
16. Dewey M, Zimmermann E, Deissenrieder F, et al. Noninvasive coronary angiography by 320-row computed tomography with lower radiation exposure and maintained diagnostic accuracy: comparison of results with cardiac catheterization in a head-to-head pilot investigation. *Circulation* 2009;120(10): 867–875.
17. Leschka S, Stolzmann P, Desbiolles L, et al. Diagnostic accuracy of high-pitch dual-source CT for the assessment of coronary stenoses: first experience. *Eur Radiol* 2009;19(12): 2896–2903.
18. Roberts WT, Wright AR, Timmis JB, Timmis AD. Safety and efficacy of a rate control protocol for cardiac CT. *Br J Radiol* 2009; 82(976):267–271.
19. Raff GL, Gallagher MJ, O'Neill WW, Goldstein JA. Diagnostic accuracy of noninvasive coronary angiography using 64-slice spiral computed tomography. *J Am Coll Cardiol* 2005;46(3):552–557.
20. Jensen CJ, Jochims M, Hunold P, et al. Assessment of left ventricular function and mass in dual-source computed tomography coronary angiography: influence of beta-blockers on left ventricular function— comparison to magnetic resonance imaging. *Eur J Radiol* doi:10.1016/j.ejrad.2009.03.027. Published online April 16, 2009.
21. Chun EJ, Lee W, Choi YH, et al. Effects of nitroglycerin on the diagnostic accuracy of electrocardiogram-gated coronary computed tomography angiography. *J Comput Assist Tomogr* 2008;32(1):86–92.
22. Schroeder S, Kopp AF, Kuettner A, et al. Influence of heart rate on vessel visibility in noninvasive coronary angiography using new multislice computed tomography: experience in 94 patients. *Clin Imaging* 2002;26(2): 106–111.
23. Giesler T, Baum U, Ropers D, et al. Non-invasive visualization of coronary arteries using contrast-enhanced multidetector CT: influence of heart rate on image quality and stenosis detection. *AJR Am J Roentgenol* 2002;179(4):911–916.
24. Hoffmann MH, Shi H, Manzke R, et al. Non-invasive coronary angiography with 16-detector row CT: effect of heart rate. *Radiology* 2005; 234(1):86–97.
25. Herzog C, Abolmaali N, Balzer JO, et al. Heart-rate-adapted image reconstruction in multidetector-row cardiac CT: influence of physiological and technical prerequisite on image quality. *Eur Radiol* 2002;12(11): 2670–2678.
26. Dewey M, Vavere AL, Arbab-Zadeh A, et al. Patient characteristics as predictors of image quality and diagnostic accuracy of MDCT compared with conventional coronary angiography for detecting coronary artery stenoses: CORE-64 Multicenter International Trial. *AJR Am J Roentgenol* 2010;194(1):93–102.

27. Bamberg F, Abbara S, Schlett CL, et al. Predictors of image quality of coronary computed tomography in the acute care setting of patients with chest pain. *Eur J Radiol* 2010;74(1):182–188.
28. Budoff MJ, Achenbach S, Blumenthal RS, et al. Assessment of coronary artery disease by cardiac computed tomography: a scientific statement from the American Heart Association Committee on Cardiovascular Imaging and Intervention, Council on Cardiovascular Radiology and Intervention, and Committee on Cardiac Imaging, Council on Clinical Cardiology. *Circulation* 2006;114(16):1761–1791.
29. Jacobs JE, Boxt LM, Desjardins B, et al. ACR practice guideline for the performance and interpretation of cardiac computed tomography (CT). *J Am Coll Radiol* 2006;3(9):677–685.
30. Leschka S, Wildermuth S, Boehm T, et al. Noninvasive coronary angiography with 64-section CT: effect of average heart rate and heart rate variability on image quality. *Radiology* 2006;241(2):378–385.
31. Dikkers R, Greuter MJ, Kristanto W, et al. Assessment of image quality of 64-row dual source versus single source CT coronary angiography on heart rate: a phantom study. *Eur J Radiol* 2009;70(1):61–68.
32. Scheffel H, Alkadhi H, Plass A, et al. Accuracy of dual-source CT coronary angiography: first experience in a high pre-test probability population without heart rate control. *Eur Radiol* 2006;16(12):2739–2747.
33. Achenbach S, Ropers D, Kuettner A, et al. Contrast-enhanced coronary artery visualization by dual-source computed tomography: initial experience. *Eur J Radiol* 2006;57(3):331–335.
34. Johnson TR, Nikolaou K, Busch S, et al. Diagnostic accuracy of dual-source computed tomography in the diagnosis of coronary artery disease. *Invest Radiol* 2007;42(10):684–691.
35. Burgstahler C, Reimann A, Brodoefel H, et al. Quantitative parameters to compare image quality of non-invasive coronary angiography with 16-slice, 64-slice, and dual-source computed tomography. *Eur Radiol* 2009;19(3):584–590.
36. Uehara M, Funabashi N, Ueda M, et al. Quality of coronary arterial 320-slice computed tomography images in subjects with chronic atrial fibrillation compared with normal sinus rhythm. *Int J Cardiol* doi:10.1016/j.ijcard.2010.02.032. Published online March 16, 2010.
37. Ropers U, Ropers D, Pflederer T, et al. Influence of heart rate on the diagnostic accuracy of dual-source computed tomography coronary angiography. *J Am Coll Cardiol* 2007;50(25):2393–2398.
38. Leber AW, Johnson T, Becker A, et al. Diagnostic accuracy of dual-source multi-slice CT coronary angiography in patients with an intermediate pretest likelihood for coronary artery disease. *Eur Heart J* 2007;28(19):2354–2360.
39. Oncel D, Oncel G, Tastan A. Effectiveness of dual-source CT coronary angiography for the evaluation of coronary artery disease in patients with atrial fibrillation: initial experience. *Radiology* 2007;245(3):703–711.
40. Tsiflikas I, Drosch T, Brodoefel H, et al. Diagnostic accuracy and image quality of cardiac dual-source computed tomography in patients with arrhythmia. *Int J Cardiol* doi:10.1016/j.ijcard.2009.01.074. Published online February 24, 2010.
41. Hausleiter J, Meyer T, Hermann F, et al. Estimated radiation dose associated with cardiac CT angiography. *JAMA* 2009;301(5):500–507.
42. Srichai MB, Hecht EM, Kim D, et al. Dual-source computed tomography angiography image quality in patients with fast heart rates. *J Cardiovasc Comput Tomogr* 2009;3(5):300–309. [Published correction appears in *J Cardiovasc Comput Tomogr* 2010;4(1):80.]
43. Weustink AC, Neeffes LA, Kyrzopoulos S, et al. Impact of heart rate frequency and variability on radiation exposure, image quality, and diagnostic performance in dual-source spiral CT coronary angiography. *Radiology* 2009;253(3):672–680.
44. Poll LW, Cohnen M, Brachten S, Ewen K, Mödder U. Dose reduction in multi-slice CT of the heart by use of ECG-controlled tube current modulation (“ECG pulsing”): phantom measurements. *Rofo* 2002;174(12):1500–1505.
45. Jakobs TF, Becker CR, Ohnesorge B, et al. Multislice helical CT of the heart with retrospective ECG gating: reduction of radiation exposure by ECG-controlled tube current modulation. *Eur Radiol* 2002;12(5):1081–1086.
46. Steigner ML, Otero HJ, Cai T, et al. Narrowing the phase window width in prospectively ECG-gated single heart beat 320-detector row coronary CT angiography. *Int J Cardiovasc Imaging* 2009;25(1):85–90.
47. Herzog BA, Husmann L, Burkhard N, et al. Low-dose CT coronary angiography using prospective ECG-triggering: impact of mean heart rate and heart rate variability on image quality. *Acad Radiol* 2009;16(1):15–21.
48. Blobel J, Baartman H, Rogalla P, Mews J, Lembcke A. Spatial and temporal resolution with 16-slice computed tomography for cardiac imaging [in German]. *Rofo* 2003;175(9):1264–1271.
49. Achenbach S, Marwan M, Ropers D, et al. Coronary computed tomography angiography with a consistent dose below 1 mSv using prospectively electrocardiogram-triggered high-pitch spiral acquisition. *Eur Heart J* 2010;31(3):340–346.
50. Lell M, Hinkmann F, Anders K, et al. High-pitch electrocardiogram-triggered computed tomography of the chest: initial results. *Invest Radiol* 2009;44(11):728–733.
51. Lell M, Marwan M, Schepis T, et al. Prospectively ECG-triggered high-pitch spiral acquisition for coronary CT angiography using dual source CT: technique and initial experience. *Eur Radiol* 2009;19(11):2576–2583.
52. Schlosser T, Mohrs OK, Magedanz A, Voigtländer T, Schmermund A, Barkhausen J. Assessment of left ventricular function and mass in patients undergoing computed tomography (CT) coronary angiography using 64-detector-row CT: comparison to magnetic resonance imaging. *Acta Radiol* 2007;48(1):30–35.
53. Schlosser T, Pagonidis K, Herborn CU, et al. Assessment of left ventricular parameters using 16-MDCT and new software for endocardial and epicardial border delineation. *AJR Am J Roentgenol* 2005;184(3):765–773.
54. Cury RC, Nieman K, Shapiro MD, et al. Comprehensive assessment of myocardial perfusion defects, regional wall motion, and left ventricular function by using 64-section multidetector CT. *Radiology* 2008;248(2):466–475.
55. Spoeck A, Bonatti J, Friedrich GJ, Schachner T, Bonaros N, Feuchtner GM. Evaluation of left ventricular function by 64-multidetector computed tomography in patients undergoing totally endoscopic coronary artery bypass grafting. *Heart Surg Forum* 2008;11(4):E218–E224.
56. Fischbach R, Juergens KU, Ozgun M, et al. Assessment of regional left ventricular function with multidetector-row computed tomography versus magnetic resonance imaging. *Eur Radiol* 2007;17(4):1009–1017.
57. Silke B, Thompson A, Riddell JG. Contrast actions of celiprolol and metoprolol on cardiac performance in normal volunteers. *Cardiovasc Drugs Ther* 1997;11(1):57–61.
58. Delius W, Wirtzfeld A, Dominiak P, Sebenig H, Blömer H, Grobecker H. Effects of acute beta-adrenoceptor blockage (metoprolol i.v.) on plasma norepinephrine concentration and hemodynamics in postmyocardial infarction patients [in German]. *Z Kardiol* 1979;68(7):441–448.

59. Murray DP, Murray RG, Rafiqi E, Littler WA. Beta-adrenergic blockade in acute myocardial infarction: a haemodynamic and radionuclide study. *Eur Heart J* 1987;8(8):845–854.
60. Colin P, Ghaleh B, Hittinger L, et al. Differential effects of heart rate reduction and beta-blockade on left ventricular relaxation during exercise. *Am J Physiol Heart Circ Physiol* 2002;282(2):H672–H679.
61. Mahabadi AA, Samy B, Seneviratne SK, et al. Quantitative assessment of left atrial volume by electrocardiographic-gated contrast-enhanced multidetector computed tomography. *J Cardiovasc Comput Tomogr* 2009;3(2):80–87.
62. Pannu HK, Alvarez W Jr, Fishman EK. Beta-blockers for cardiac CT: a primer for the radiologist. *AJR Am J Roentgenol* 2006;186(6 suppl 2):S341–S345.
63. Takakuwa KM, Halpern EJ, Gingold EL, Levin DC, Shofer FS. Radiation dose in a “triple rule-out” coronary CT angiography protocol of emergency department patients using 64-MDCT: the impact of ECG-based tube current modulation on age, sex, and body mass index. *AJR Am J Roentgenol* 2009;192(4):866–872.
64. Bastarriga G, Thilo C, Headden GF, Zwerner PL, Costello P, Schoepf UJ. Cardiac CT in the assessment of acute chest pain in the emergency department. *AJR Am J Roentgenol* 2009;193(2):397–409.
65. López-Sendón J, Swedberg K, McMurray J, et al. Expert consensus document on beta-adrenergic receptor blockers. *Eur Heart J* 2004;25(15):1341–1362.
66. Singh J, Daftary A. Iodinated contrast media and their adverse reactions. *J Nucl Med Technol* 2008;36(2):69–74; quiz 76–77.
67. DiFrancesco D. Funny channels in the control of cardiac rhythm and mode of action of selective blockers. *Pharmacol Res* 2006;53(5):399–406.
68. Tardif JC, Ponikowski P, Kahan T; ASSOCIATE Study Investigators. Efficacy of the I(f) current inhibitor ivabradine in patients with chronic stable angina receiving beta-blocker therapy: a 4-month, randomized, placebo-controlled trial. *Eur Heart J* 2009;30(5):540–548.
69. Tardif J, Camm A. Dependence of heart rate reduction with the I(f) inhibitor ivabradine on pretreatment resting heart rate [abstr]. *Eur Heart J* 2007;28(suppl):321.
70. Savelieva I, Borer J, Camm A. Low incidence of severe bradycardia during therapy with ivabradine: the heart rate lowering effect is limited by baseline heart rate [abstr]. *Eur Heart J* 2007;28(suppl):219.